A Retrospective Evaluation of Transforming Powder Dressing in the Treatment of Non-Healing Diabetic Foot Ulcers

Chitang J Joshi, Shin Young Yu, Joshua Weissman, Peter Ullrich, Robert D Galiano

Northwestern Feinberg School of Medicine, Division of Plastic and Reconstructive Surgery

Symposium of Advanced Wound Care (SAWC) | Fall 2021 Meeting

Introduction

Diabetes mellitus (DM) is a serious chronic disease with an estimated worldwide prevalence of 2.8%. Diabetic foot ulcers (DFUs) are a common complication of DM caused by varying factors including poor glycemic control, peripheral neuropathy, reduced sweating, poor sensation and inadequate arterial circulation. Data indicates that 10-15% DFUs remain chronically active and up to 24% of them eventually lead to limb amputations due to foot infections.

Transforming powder dressing (TPD) forms a non-occlusive barrier on the wound bed that helps optimize wound moisture to promote healing. Extended wear time reduces dressing changes, infection risk and complications, presenting a promising new wound treatment modality.

Materials and Methods

We used a novel methacrylate-based transforming powder dressing, which transforms in-situ to a shape-retentive wound matrix once in contact with moisture. (Altrazeal® TPD, ULURU Inc.).

A retrospective evaluation was conducted for 17 patients with non-healing, Wagner Grade 2-3 DFUs treated with standard of care therapies. Dressing change frequency and time to closure were evaluated.

Results

52-year-old male with non-healing Wagner grade 2 ulcer for five months receiving daily dressing changes. Pain and exudation reduced significantly after one TPD application. Two TPD changes were required over the four-week period.

68-year-old male with non-healing Wagner Grade 3 DFU for one year. Patient expressed pain reduction immediately after TPD application.

Wound area reduced significantly by first dressing change (Day 9) with 75% reduction by the third change (Day 40).

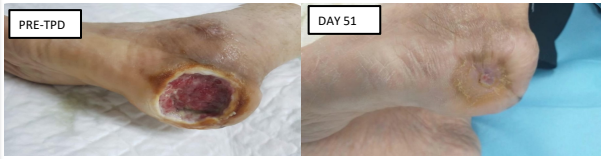

59-year-old female with type II DM, CVD and non-healing Wagner Grade 3 ulcer for three months. A total of eight dressings were utilized over seven weeks.

Summary Results: TPD Treatment Outcomes for Wagner

Wagner Grade Ulcer Classifcation	Total Cases Analyzed	Average Days to Healing	Average Number of Dressing Changes	Average Days Between Dressing Changes
All	17	46	5.9	10
3	13	48	6.2	10
2	4	37	5.3	10

Historical data on 17 patients (mean age of 58) revealed 13 patients (77%) with severe Wagner Grade 3 DFUs and 4 (23%) had Wagner Grade 2 DFUs. The hard-to-heal DFUs had a mean duration of 33 months (range: 4 days – 18 years). TPD was changed on a weekly to monthly schedule, based on the clinician's judgement and individual patient needs. The mean number of dressing changes was 5.9 and the mean time to heal was 45.7 days. All patients displayed accelerated wound closure and avoided amputations.

Conclusion

TPD presented a safe and effective modality for treatment of hard-to-heal DFUs; significantly reducing the duration of healing, patient pain and the number of dressing changes.

References

1. Nelson EA, Wright-Hughes A, Brown S, et al. Concordance in diabetic foot ulceration: a cross-sectional study of agreement between wound swabbing and tissue sampling in infected ulcers. Southampton (UK): NIHR Journals Library; 2016 Nov. (Health Technology Assessment, No. 20.82.) Chapter 1
2. Alexiadou, K., & Doupis, J. (2012). Management of diabetic foot ulcers. *Diabetes therapy : research, treatment and education of diabetes and related disorders*, *3*(1), 4.
3.Palfreyman, Simon, E Andrea Nelson, and Jonathan A Michaels. "Dressings for Venous Leg Ulcers: Systematic Review and Meta-Analysis." *BMJ* 335.7613 (2007): 244–248. Web.
4. Sood, A., Granick, M. S., & Tomaselli, N. L. (2014). Wound Dressings and Comparative Effectiveness Data. *Advances in wound care*, *3*(8), 511–529

Northwestern

Contact: chitang.joshi@northwestern.edu

Acknowledgement: This poster was developed and presented in collaboration with ULURU Inc.

For application instructions and risks of this device refer to Altrazeal Instructions for Use | EDU - 0016

A Novel Transforming Powder Dressing for Healing Chronic Wounds of Multiple Wound Etiologies

David Bickers CRNP, CWOCN-AP | University of Pittsburgh Medical Center, Altoona PA

WOCNext 2022 Meeting, Fort Worth, TX | June 5-8, 2022

CHALLENGE

Delayed wound healing results from an imbalance occurring during healing stages, often resulting in conversion of an acute wound to a chronic non-healing wound.[1,2] Chronic wounds are significantly more complicated to heal than acute wounds.[2] In the US alone, chronic wounds currently affect 6.7 million people, with annual healthcare costs exceeding 50 billion dollars.[3]

Evidenced based clinical principles for optimizing wound healing include: (1) maintaining a moist (but not wet) wound environment, (2) permitting gaseous and fluid exchange while providing mechanical and bacterial protection, and (3) utilizing a dressing that is non-adherent to the wound, easy to use, comfortable and pain-free for the patient. When standard of care (SOC) therapy fails to heal a wound, alternate treatment strategies must be considered.

METHOD AND MATERIALS

We present a case series which evaluates the clinical outcomes of 3 patients with chronic wounds of different etiologies which were refractory to prescribed SOC therapy (burn, 2 diabetic foot ulcers and trauma wound).

All wounds had deteriorated or showed no clinical progress prior to conversion from SOC dressings to Transforming Powder Dressing (TPD). For purposes of consistency in our assessment, the conversion of the primary dressing from SOC to TPD was the only wound treatment factor modified.

TPD is a novel powder dressing comprised primarily of biocompatible polymers (same as those used in contact lenses). Upon hydration, TPD granules aggregate to form a moist, oxygen-permeable matrix that protects the wound from contamination while helping to manage excess exudate through vapor transpiration. Once applied, TPD may be left in place for up to 30 days and additional powder may be added ("topped off") as needed without requiring primary dressing changes. Simple secondary dressings may be used in areas of high exudation or friction. TPD dries and flakes off as the wound heals.

SUMMARY RESULTS

- In the cases presented, each of which was refractory to SOC therapy, all wounds healed and came to complete closure after treatment with TPD.
- Average time to heal for all 4 wounds after initial treatment with TPD was 47 days.

PATIENT 1: BURN

- **History:** 62 y/o male with DMT2, venous insufficiency, mild lymphedema, and deep partial thickness burn on ankle / LLE after catching sock on fire while welding
- **Wound Size:** 1.5cm x 1.5cm x 0.2cm
- **Wound Duration:** > 8 weeks (60 days)
- **Prior Treatment:** Silver Sulfadiazine 1% cream and non-adherent dressing multiple times a week
- **TPD Treatment**: Weekly applications
- **Outcome:** Fully healed in 42 days with TPD

PATIENT 2: DIABETIC FOOT ULCER

- **History:** 62 y/o female with IDDM T2, lymphedema,
- neuropathy, BMI 45.6, and two plantar DFUs
- **Wound Size:** 0.5cm x 0.5cm x 0.7cm (heel) | 1.6cm x 1.2cm x 1.2cm (5th metatarsal)
- **Wound Duration**: ~1.5 to 2 years
- **Prior Treatment**: Total contact cast with foam dressings
- **TPD Treatment**: Weekly applications
- **Outcomes**: Both ulcers fully healed within 35 days (average)
  - **Heel Ulcer:** Closed in 33 days with TPD
  - **Submetatarsal 5 Ulcer:** Closed in 37 days with TPD

PATIENT 3: TRAUMA

- **History:** 52 y/o male with CAD, renal disease, smoking disorder, and trauma wound to anterior knee
- **Wound Size:** 2.5cm x 2cm (eschar)
- **Wound Duration:** > 6 weeks (45 days)
- **Prior Treatments:** Mupirocin calcium ointment, medical grade honey, cortisone applied multiple times a week
- **TPD Treatment**: Weekly applications
- **Outcomes:** Fully healed in 63 days

CONCLUSION

The use of TPD as a universal primary dressing on non-healing wounds of different etiologies significantly improved healing times with reduced frequency of dressing changes and brought each of the non-healing wounds to complete closure. No adverse events were reported.

REFERENCES AND ACKNOWLEDGEMENTS

1. Ciancio LC, Barillo DJ, Kerans RD, et al. Guidelines for Burn Care Under Austere Conditions: Surgical and Nonsurgical Wound Management. J Burn Care Res. 2017 JUL/Aug; 38 (4); 203-214
2. Han G, Ceilley R. Chronic Wound Healing: A Review of Current Management and Treatments. Adv Ther 34, 599-610 (2017). http://doi.org/10.1007/s12325-017-0478-y. Accessed online 20APR2022
3. Wound Care Awareness Week Highlights of the Chronic Wound Epidemic in US; Businesswire.com/news/home/20160607006326/en/Wound-Care-Awareness-Week-Highlight

Acknowledgements: This poster was created in collaboration with ULURU Inc. No compensation was paid to the author for development of this poster.

Gregory Bohn, MD FACS Medical Director
Trinity Medical Center
Bettendorf, Iowa

Transforming Powder Dressing combined with Total Contact Cast may shorten days to heal Wagner Grade 2 Neuropathic Diabetic Foot Ulcers.

Purpose:

This poster presentation illustrates the use of a new Transforming Powder dressing combined with off loading total contact casting to bring about healing of Wagner Grade 2 Diabetic Foot ulcers.

Objectives:

At the conclusion of this presentation the participant will be able to:
1. Evaluate the use of Transforming Powder Dressing with contact casting.
2. Demonstrate the application of Transforming Powder dressing.
3. Review healing trajectories of Diabetic Neuropathic Foot Ulcers treated with Transforming Powder Dressing and contact cast.

Abstract:

Total contact casting has been considered the gold standard for offloading Diabetic Neuropathic Foot Ulcers. Typical dressing material for moist wound healing applied under a contact cast has been petroleum gauze as it will maintain that environment for the length of the cast application. A new dressing material is available that may influence healing by its unique ability to manage moisture while maintaining an optimal wound environment. The High Moisture Transpiration Rate of this material creates a negative pressure effect of 200-300 milli torr at the wound surface, 100 milli torr of negative pressure is enough to activate wound fibroblasts. This unique and important aspect of this particular material may stimulate wound fibroblasts and bring about accelerated healing. The fact that the dressing material can stay in place for up to 30 days makes it an attractive choice for use in longer term applications like contact cast application. Cadexomer iodine and becalpermin have been combined with this material at the time of application in order to manage Wagner Grade 2 Diabetic Foot Ulcers. This presentation discusses the use of this new wound dressing technology in conjunction with the use of "gold standard" contact cast offloading in treating Diabetic Wagner Grade 2 Neuropathic Foot Ulcers.

Methods and Materials:

An easy to apply contact cast system and a new Transforming Powder Dressing material were used to heal Diabetic Grade 2 neuropathic ulcers. Transforming Powder Dressing was applied to neuropathic Wagner Grade 2 foot wounds, covered with wound veil and foam supplied with the kit. The initial cast was removed and the leg inspected for cast related at 72 hours. Wounds were followed weekly and measured and photographed. Simple wound measurements were used to monitor healing and track progress of the wounds. Wound Volume was calculated using the formula Width X Length X Depth X .8. Wound progress was examined and monitored with use of Transforming Powder Dressing and easy to apply Contact Cast. Vascular integrity was assessed by ABI measurement. Patients with less than .8 ABI were referred for vascular assessment. Patients were assessed for mobility and suitability for contact cast application. Six cases are reported.

Results:

Patients were either started initially in contact cast and powder therapy or failing other treatment and switched at the time of their 30 day review. Five of 6 patients (1,2,3,4,6) healed within 2 weeks with combination Transforming Powder and contact cast. Patient 5 had healed by week 3 and had decreased wound volume by 97.2% at week 2. There were no cast complications in this group. Reduction in wound volume relative to weeks in wound care is summarized in table 1. Two patients had declined initial use of contact casting in favor of a DH walker for offloading. Both had not shown sufficient healing by 30 day review to predict healing at 14 weeks. Both patients agreed to contact casting after their 30 day review and healed in 2 weeks with Transforming Powder dressing and easy to apply contact casting. Days to heal for the group was 15.2 days.

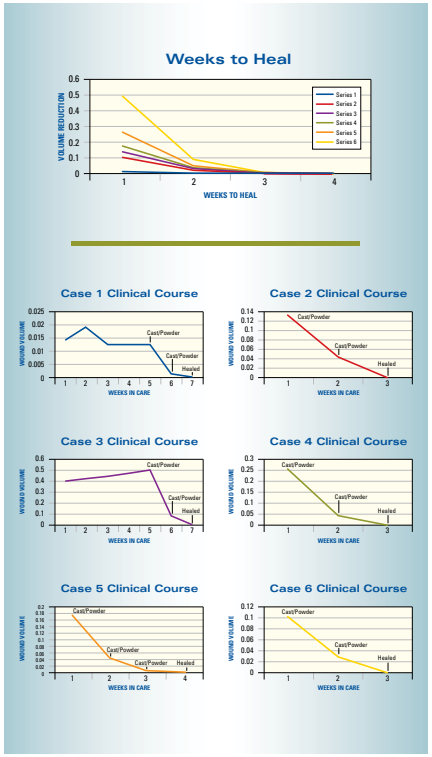

CASE STUDY

Transforming powder dressing applied to wound

Transforming powder dressing combined with cadexomer iodine

Transforming powder dressing combined with cadexomer iodine

Easy to apply contact cast with boot

Conclusion:

Since instituting easy contact casting and Transforming Powder dressing in our clinic, we have seen an improvement in our ability to heal diabetic Wagner grade 2 lesions. When patients are in a removable offloading orthotic, compliance is always an issue. We found that contact casting ensured compliance with offloading and had a beneficial effect on healing. Offloading is improved by redistributing force onto the leg itself.

We have observed an effect from Transforming Powder dressing and its impact on healing. The property of the material to create a low but real negative pressure at the wound dressing interface may impact on the activity of wound fibroblasts and positively affect healing. The ability to combine the material with actives could be beneficial to healing as well. The material can be left in place for up to 30 days. The long wear time of this material makes it an attractive dressing choice under contact casting. "Days to Heal" decreased from 41 days to 15 days since instituting easy to apply contact casting and Transforming Powder dressing.

References:

1.) St. John J V, Brown S A.,Hatef DA, Unzeitig A W, Noble D, Waller L K, and Ponder B C. Formulation development and in vivo testing of a novel powder wound dressing. The University of Texas Southwestern Medical Center at Dallas, Department of Plastic Surgery, 1801 Inwood Rd., Dallas, TX 75390

2.) St John J V, Altrazeal TM : Transforming Clinical Wound Management: From Science to Outcomes with an Innovative Powder Dressing. Clinical Symposium on Advances in Skin & Wound Care. Oct 29, 2008 Las Vegas Nevada.

3.) Nabuurs-Franssen MH, Sleegers R, Huijberts M SP, Wijnen W, Sanders AP, Walenkamp G, Schaper NC, Total Contact Casting of the Diabetic Foot in Daily Practice : A Prospective Follow Up Study. Diabetes Care Feb 2005 (6):2 p 243-47.

4.) Petre M, Tokar P, Kostar D, Cavanagh PR, Revisiting the Total Contact Cast : Maximizing off-loading by wound isolation. Diabetes Care Apr 2005 (28):4 p 929- 30.

5.) Myerson M, Papa J, Eaton K, Wilson K, The Total Contact Cast for Management of Neuropathic Plantar Ulceration of the Foot. J Bone Joint Surg Am. 1992;74:261-269.

TRINITY
IOWA HEALTH SYSTEM
A better experience.

The Combined Effect Of The Offloading Felt Pad System And A Novel Powder Wound Dressing On Plantar Ulcers

Authors: Lesly D. Robinson, DPM[1], Tracey C. Vlahovic, DPM[1], Frank Oware, BS[2], Felicia Bock, BS[2], Antonia DeGeorge McClune, BA[2], Banafsheh Baharloo, BS[2]

.Affiliation: [1]Faculty, [2]Fourth year students; Temple University School of Podiatric Medicine, Philadelphia, PA, 19107

Introduction

Off-loading plantar diabetic foot ulcers can be a challenge for both the patient and practitioner. Challenges involved in treating these plantar wounds involve both short term and long term placement and control of the dressing and compliance. The implementation of a novel powder wound dressing and felt padding system demonstrated assistance in all of the challenges. The physical properties of this powder wound dressing are unique due to its ability to form a solid, non-resorbable moist wound dressing after contact with wound exudate or saline. The 3D (Hapla, Cuxson Gerrard) felt padding system is a novel off-loading system that allows the patient to have access to an aperture for wound dressing changes, while still maintaining pressure redistribution.

Methodology:

The physical and chemical properties of a novel powder dressing formulated as polymer particles and the padding system have previously been studied. The plantar diabetic foot wounds were treated with the novel powder dressing followed by the felt pad system once weekly for four weeks. The patient was educated on dressing changes at home while keeping the felt padding intact.

Case 1

63 y.o. IDDM African American male presented with chronic Wagner-Grade II ulcer on the plantar surface of the third metatarsal of the right foot. The ulcer has been present for 2 ½ years. Patient is non-compliant with offloading.

Visit 1 -3/24/10
Size of wound- 2.8cm length, Width 1.3, Depth 0. 2cm
Exudate- Low
Wound Bed- 90% granular/ 10% Fibrous
Wound Margin: Hyperkeratotic
Treatment
Wound Debrided
Dressings applied: Castellani's paint peri-wound, Altrazeal applied to the base of the wound
Offloading device: Hapla 3D system and surgical shoe

Visit 2: 3/31/10:
Patient presents with Hapla 3D system still in place, dry , clean, and intact.
Size of wound- 1.8cm length, Width 1.2, Depth 0. 2cm
Exudate- Low
Wound Bed- 100% granular
Wound Margin: Hyperkeratotic and Macerated
Treatment
Wound Debrided
Dressings applied: Castellani's paint peri-wound, Altrazeal applied to the base of the wound
Offloading device: Hapla 3D system and surgical shoe

Visit 3: 4/7/10
Size of wound- 1.7 cm length, Width 1.7, Depth 0. 2cm
Exudate- Low
Wound Bed- 100% granular
Wound Margin: Hyperkeratotic and Macerated
Treatment
Wound Debrided
Dressings applied: Castellani's paint peri-wound, Altrazeal applied to the base of the wound
Offloading device: Hapla 3D system and surgical shoe

Visit 4 : 5/19/10
Size of wound- 1.4 cm length, Width 1.0, Depth 0. 2cm
Exudate- Low
Wound Bed- 100% granular
Wound Margin: Hyperkeratotic
Treatment
Dressings applied: Castellani's paint peri-wound, Altrazeal applied to the base of the wound
Offloading device: Hapla 3D system and surgical shoe

Day 7

Day 7

Day 57

Case 2

40 year-old male presented with plantar verruca that has been curretaged and electrodessicated. Patient was compliant and ambulated with crutches for four weeks. Patient had no pertinent past medical history.

Visit #1 3/16/2010
Right foot ulcer x 2; location: plantar heel distal and proximal
Type of wound: post-surgical
Wound bed: granular
Wound margin: healthy
Treatment
Wound cleansed and Altrazeal with Hapla 3D system and surgical shoe applied. Patient to keep foot dry and not remove dressings. Weight bearing as tolerated.
.
Visit #3 4/1/2010
Right foot ulcer x 2; location: plantar heel distal and proximal
Type of wound: post-surgical
Wound bed: granular
Wound margin: macerated and slightly hyperkeratotic
Treatment
Wound cleansed and Altrazeal with Hapla 3D system and surgical shoe applied. Weight bearing as tolerated

Visit # 6 4/23/2020
Right foot ulcer x 1; location: plantar heel distal; plantar heel proximal ulcer resolved
Type of wound: post-surgical
Wound bed: granular
Wound margin: macerated and slightly hyperkeratotic
Treatment
Wound cleansed and Altrazeal with Hapla 3D system and surgical shoe applied. Weight bearing as tolerated

Visit #10 5/18/2010
Right foot ulcer x 1; location: plantar heel distal
Type of wound: post-surgical
Wound bed: granular
Wound margin: macerated and slightly hyperkeratotic
Treatmen:
Wound cleansed and Altrazeal with Hapla 3D system and surgical shoe applied. Weight bearing as tolerated

Visit # 11 5/25/2010
Right foot ulcer x 2 resolved
Type of wound: post-surgical
Treatment
Patient is to keep the skin slightly moist with a fine layer of Aquaphor healing ointment daily. Weight bearing as tolerated
Throughout the therapy, the patient had no pain or problems ambulating using the combination of the dressing, felt 3D dressing, and surgical shoe.

Day 0

Day 7

Day 39

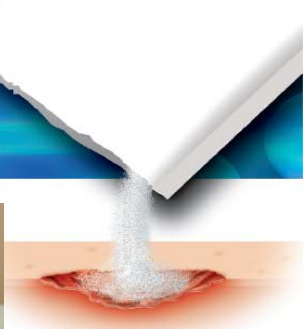

Case 1 Conclusion:
The Hapla 3D system,an assisted walking offloading device in combination with
Altrazeal, is an effective to treat a plantar neuropathic ulcer. In less than 4 weeks the patient's ulcer decreased in size: 1.4cm in length and 0.3cm in width. Moreover, after 1 week of treating the ulcer with Altrazeal, the ulcer base became 100% granular..

Case 2 Conclusion:
The combination of this novel powder wound dressing and off-loading felt padding system allow for use of the transforming wound dressing in plantar wounds. The combination dressing demonstrates the capability to remain in contact with the wound bed for periods of up to seven days between dressing changes. More importantly, it provided a painless, efficient, and protective wound treatment that not only assisted in wound closure, but also in wound preparation for further interventions

References:
• St John J. "The Design and Performance of Nanoflex™ Transforming Powder Dressing: A Novel Wound Care Management System", presented at the Clinical Symposium on Advances in Skin and Wound Care, Las Vegas, 2008.
• Niezgoda, J. "Altrazeal™ A Transforming Powder Wound Dressing: The Clinical Experience," presented at the Clinical Symposium on Advances in Skin and Wound Care, Las Vegas, 2008.

Aggregate Wound Dressing in the Management of Soft Tissue Wounds

Ryan H. Fitzgerald[2] DPM, Manish Bharara[1] PhD, Joseph Mills[1] MD, David G. Armstrong[1] DPM, PhD

[1]Southern Arizona Limb Salvage Alliance (SALSA), College of Medicine at University of Arizona, Tucson, AZ 85724

[2]Foot & Ankle Surgery, Washington Hospital Center, Washington DC

Abstract

This investigation presents the clinical outcome following the utilization of aggregate wound dressing following radical debridement in a 43-year-old Native American female who presented with a case of necrotizing fasciitis and a history of diabetes mellitus.

Clinical Course

Following serial debridement, the patient was left with a large dorsal foot wound and a partial second-ray amputation. A foot-narrowing reconstructive procedure was then performed, and the patient was transitioned through a multitude of advanced wound healing modalities to stimulate wound healing to the large dorsal wound. NPWT was initially utilized in the post-operative setting to control drainage and to promote granulation tissue, however the patient was transitioned to a aggregate wound dressing on post-op day 4. Approximately two and a half weeks following initial presentation, the patient was observed to have developed a healthy granular base, a STSG was harvested and applied to the dorsal wound.

Clinical Images

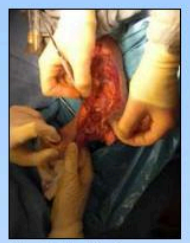

Fig. 1: Radical debridement following presentation with necrotizing fasciitis.

Fig. 2: Partial second ray amputation with large plantar deficit.

Fig. 3: Extensive dorsal soft tissue loss.

Fig. 4: Foot-narrowing procedure to reduce defect following partial 2nd ray amputation.

Fig. 5: NPWT was initially utilized to promote formation of granulation tissue.

Fig. 6: 1-week post-op following initial radical debridement.

Fig. 7: Aggregate powder applied to the dorsal soft tissue wound.

Results

Following radical debridement for necrotizing fasciitis and subsequent reconstructive efforts and progression through several wound healing modalities, the patient went on to complete healing in 9 weeks.

The patient reported a decrease in pain associated with dressing changes transitioning between the NPWT and the use of aggregate wound dressing. We hypothesize that this pain reduction is due to a light cooling effect of the moisture controlling dressing and subsequent reduction in inflammation as well as the total contact nature of the dressing.

Fig. 8: Aggregate powder in deaggregated state.

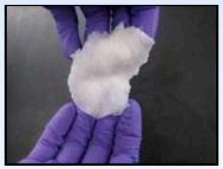

Fig. 9: Exposure to ionized fluid media initiates aggregation.

Fig. 10: STSG was applied to the dorsal foot wound at 2 1/2 weeks following initial presentation.

Fig. 11: 7-weeks following initial presentation, the patient demonstrates 80% healing. The patient was 100% healed at 9 weeks.

Conclusion

Wound dressing was utilized to provide moisture control and to promote wound healing following radical debridement of the left lower extremity. This technology is a recently developed advanced wound healing modality that demonstrates promise in the management of acute and chronic exudating wounds. Upon activation with serum or exudate, the subsequent powder dressing provides moisture control for actively exudating wounds, in addition to reducing the risk of bacterial contamination. While this technology is in it is early stages, there is significant potential for usage of the powder dressing in the management of complex soft tissue wounds to serve as primary wound dressing as well as providing a delivery platform for analgesics, antimicrobials, and proangiogenic compounds, and as such further research is necessary.

References

1. Armstrong, D.G. and B.A. Lavery, Clinical trials in the treatment of diabetic foot infection. Diabetes Technol Ther, 2004. 6(3): p. 357-71.
2. Ryan-Hunt, K.M., et al., [Re-ingrowth of toenail stump 2 years following amputation]. Ugeskr Laeger, 1999. 161(6): p. 859-60.
3. Armstrong, D.G. and B.A. Lavery, Diabetic foot infections: A special medical and surgical management at Ari Mount. J, 2004. 1(2): p. 123-32.
4. Peng, M., et al., [The application of negative pressure wound therapy in the treatment of chronic osteomyelitis]. Zhonghua Wai Ke Za Zhi, 2009. 47(4): p. 272-5.
5. Lavery, L.A., et al., Home-based foot ulcer monitoring for patients with diabetes. Diabetes Care, 2008. 31(5): p. 1000-1.
6. Bowler, P.G., B.A. Duerden, and D.G. Armstrong, Wound microbiology and associated approaches to wound management. Clin Microbiol Rev, 2001. 14(2): p. 244-69.
7. Armstrong, D.G. and L.A. Lavery, Negative pressure wound therapy after partial diabetic foot amputation: a multicentre, randomised controlled trial. Lancet, 2005. 366(9498): p. 1704-10.
8. Armstrong, D.G., et al., Quantifying the energy expended over wound therapy [VAWT] or the standard of care in patients with diabetic foot wounds. J Am Podiatr Med Assoc, 2005. 95(3): p. 255-60.
9. Kantorski, K., et al., Disease-specific and non-disease-specific models of cost-effectiveness: a cost-utility analysis of vacuum-assisted closure therapy for diabetic foot ulcers. Am J Surg, 2008. 196(6): p. 915-23.
10. Lima, A.C., et al., Hyperosmotic reversible trial: glycemic control by non-invasive osmotic influence within high tensions of air: methodological clues and non-mere words on patients with diabetes. Einstein (Sao Paulo), 2009. 7(2): p. 113-8.
11. Brinkley, M.S., et al., The use of wound bed debridement 1-2 years as a salvage approach for wound closure after revised ray amputations. Clin Podiatr Med Surg, 2008. 25(3): p. 427-33, vii.
12. Ayello, E.A., Does evidence for an ideal dressing exist? Ostomy Wound Manage, 2008. 54(12): p. 12-3.
13. Peters, E.J., et al., Debridement and wound healing. Ostomy Wound Manage, 2008. 54(8): p. 30-1.
14. Armstrong, D.G., L.A. Lavery, and A.J. Boulton, Negative pressure wound therapy via vacuum-assisted closure following partial foot amputation: what is the role of wound chronicity? Int Wound J, 2007. 4(1): p. 79-85.
15. Baumeister, S., et al., [Use rate of plaster cast immobilization versus surgery within an interdisciplinary foot ulcer treatment concept in diabetic patients]. Chirurg, 2004. 75(6): p. 570-80.
16. Dogan, Z., Use of vacuum dressing systems to accelerate skin wound healing. J Drug Target, 2008. 16(8): p. 637-46.
17. Gurtner, M.C. and R.R. Kelly, Negative pressure wound therapy: basic physiological principles. Chron Wound Wound Manag, 2008. 4(6): p. 507-11.
18. Venugopal, P., et al., Polyvinyl butyral-based polymeric wet ophthalmic for topical delivery of timolol: preparation and characterization. Pharmazie, 2001. 56(1): p. 21-6.

Contact:
Dr. Ryan H. Fitzgerald, DPM
Washington Hospital Center, Washington DC
Dr.Ryan.Fitzgerald@gmail.com

Properties of a Novel Powder Wound Dressing and Clinical Experience in Diabetic Foot Ulcers

Gregory A. Bohn, MD FACS. Medical Director,
Trinity Center for Wound Care and Hyperbaric Medicine, Bettendorf, IA
Sid Sharma DPM FAPWCA, All County Podiatry PC, NY, NY
Gianni Persich DPM FAPWCA, All County Podiatry PC, NY, NY
John V. St. John, PhD, ULURU, Inc. Addison, Texas

Introduction

Purpose – The purpose of this presentation is to show the physical and chemical characteristics of a unique powder wound dressing and to demonstrate the use of this dressing in the treatment of diabetic foot ulcers (DFU's).

Method – We report on the properties of a novel powder dressing formulated of polymer particles, and clinical experience in the treatment of diabetic foot ulcers with and without contact casts.

Results – The physical properties of this powder wound dressing are unique when compared to other dressing materials. When the powder interacts with wound exudate, an instantaneous and irreversible aggregation of the powder particles occurs. This aggregation is a physical transformation from powder form into a solid, non-resorbable, porous moist wound dressing. The structure of the intact dressing provides intimate contact to surface irregularities at the sub cellular level sealing the wound in a manner that is not possible with other dressing materials. The intact moist dressing makes use of capillary forces inherent to the aggregated particles to provide a strong adhesion to the wound surface. This adhesive force coupled with the sealing properties result in a primary dressing that in most cases requires no secondary covering to remain in place and isolate the wound from exogenous bacteria. We report on four separate clinical cases of diabetic foot ulcers treated with this wound dressing. Two cases involved the powder wound dressing applied to heel or Achilles DFU's with coverage of the aggregated dressing using a veil and gauze pads then offloading during healing. Two cases used the powder wound dressing on plantar surfaces with total contact casts applied over the dressing. In all four cases, the DFU's were followed to healing.

Nanoflex Technology

Nanoflex technology is the basis for a powder wound dressing product. The dressing components consist of polymer particles. The polymer particles are composed of 85% poly-2-hydroxyethylmethacrylate (pHEMA) and 15% poly-2-hydroxypropyl methacrylate (pHPMA). The polymers pHEMA and pHPMA are both non-resorbable, non-degradable, hydrophilic crosslinked polymers that are in the ratio of 85:15 by weight and maintain a fluid content of approximately 68% by weight of the matrix. The powder aggregates (coalesces) immediately and irreversibly from polymer particles into an intact dressing. There is no chemical reaction during dressing formation. The dressing binds together physically and not chemically and remains bound together with the wound exudate through hydrophilic/hydrophobic interactions, hydrogen bonding and Van Der Waal forces. An illustration of the dressing displaying the mechanism of action is shown.

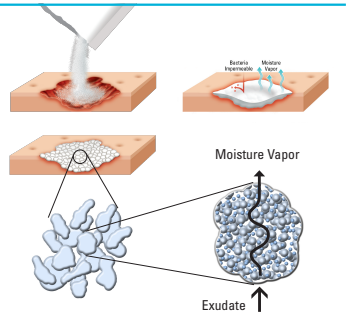

DFU Treatment - Case Study

Patient 1: 47 yo Insulin dependent Diabetic Male maintained on Humulin R presented with a diabetic Wagner grade 2 lesion on the plantar surface of the fifth metatarsal phalangeal joint . Non-smoker. Current wound present for 24 weeks, starting as a blister. Wound volume stalled after treatment with tissue substitute. Powder wound dressing applied and dramatic improvement occurred with healing by week 4 of dressing treatment with weekly dressing changes.

DAY 0 | WEEK 2 | WEEK 3

Patient 2: 53 yo insulin dependent diabetic male with past history of plantar Neuropathic ulcers presented to the wound clinic with a new Wagner grade three lesion to the plantar surface of the left great toe. Powder wound dressing applied and covered with veil. Wound healed by week four.

DAY 0 | APPLICATION 1 | WEEK 3

Patient 3: 58 yo male with history of DM, HTN. Wound is a DFU on the lateral aspect of his left heel. On initial consult (week 1) Pt. had one ulcer measuring 1.0x0.4x0.2cm. He had hyperkeratotic tissue surrounding the wound, no undermining, no probing to bone. Both wounds were debrided with a #15 blade, cleansed with sterile saline. The powder dressing was applied to the wound and covered with wound veil. The wound was covered with non-stick pad, kling and coban. At week 2 the patient developed a second adjacent ulcer. Pt. had the first ulcer measuring 0.6x0.3x0.1cm and the second wound measured 0.3x0.2x0.2 cm. At week 3, the patients newly developed ulcer 2 was closed. At week 4, the first ulcer had closed.

DAY 0 | WEEK 1 | WEEK 3

Patient 4: 64 year old female with history of DM, HTN. Wound was surgical and result of achilles repair and was present for four weeks. The wound was debrided with a #15 blade, and cleaned. The powder dressing was then applied to the wound and then covered with Smith and Nephew's wound veil. Using a spray device, the saline was sprayed on the wound veil allowing the altrazeal to set in. The wound was then covered with Johnson & Johnson 2x3inch non-stick pad, kling and coban. A Posterior splint was also applied to the patient due to protect the tendon repair. Patient was offloaded with crutches. At followup one week after the initial application the wound was closed.

DAY 0 | WEEK 1

This study was sponsored by ULURU, Inc. All wounds were treated with Altrazeal™ Transforming Powder Dressing.

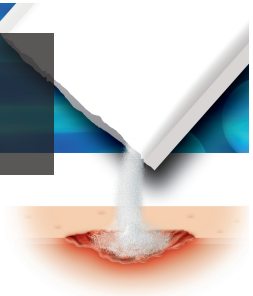

Conclusions

A novel powder wound dressing was evaluated as a treatment option for the coverage, healing and protection of DFU's. For the cases presented, the dressing was applied by pouring the powder onto the moist wound surface. The powder aggregated into a uniform dressing with the use of saline. In all four cases, the aggregated dressing was covered with a veil and the patient was instructed to offload the ulcer. For each presented case, the dressing was removed weekly and all wounds were followed to closure. This novel powder dressing can be applied to diabetic foot ulcers and held in place with a porous veil for periods of up to one week and the wound can be treated to closure.

2009 CSAWC San Antonio, Texas

John Jackalone, DPM
Co-Director
Wound Healing Center at New Island Hospital, Bethpage, NY

Combination of a Novel Powder Dressing* with Hyperbaric Oxygen in the Treatment of Diabetic Foot Ulcers and Chronic Non-Healing Wounds

Purpose:

The purpose of this evaluation was to determine if a novel powder wound dressing can be applied in conjunction with Hyperbaric Oxygen (HBO) therapy as a treatment for non-healing debrided ulcers of the foot.

Methods:

Patients were assessed and proper wound care technique including sharp debridement, resolution of infection and overall care of health was performed prior to initiation of treatment with HBO and the powder dressing.

The dressing was applied to the surface of a clean, debrided wound and left in place typically without a secondary dressing. HBO Therapy was initiated with the dressing in place. The dressing was changed weekly and the wounds were photographed.

Wound surface area was calculated by digitizing the images using the included ruler as a scalar and pixel area was converted to surface area in the image using NIH Image J with aspect ratios accounted for in the images.

Treatment:

Patient 1: 56 year old male presenting with Diabetes Mellitus and peripheral vascular disease (PVD). The ulcer was present on the right heel and had remained in stasis for over 1 year. The wound was debrided and the powder dressing was applied in conjunction with HBO therapy at regular intervals. The dressing was changed weekly. At week 7, the wound achieved closure with some soft tissue deficit on the surface.

Patient 2: 45 year old female presenting with DM and PVD. Patient was recently discharged from the hospital following a metatarsal head resection that resulted in dehiscence. The wound was complicated by tunneling resulting in communication through an original plantar ulcer into the remaining metatarsal shaft. The wound was debrided and the powder dressing and HBO therapy was initiated. The dressing was changed weekly with regular HBO therapy. By week 2 the plantar wound resolved and the tunneling through the resection was resolved. Closure was achieved by week 8 with weekly dressing changes.

Patient 3: 20 year old female, smoker presented with wound as a result of a neuroma excision and non-healing wound between the second and third metatarsal in stasis for three months. The wound was treated with HBO and the powder dressing with the dressing changed weekly. The wound showed increased granulation tissue initially and then was resolved to closure.

Patient 1

Day 0

Week 2

Week 6

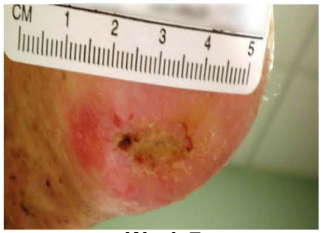
Week 7

Patient 2

Day 0

Week 2

Week 6

Week 8

Patient 3

Day 0

Week 2

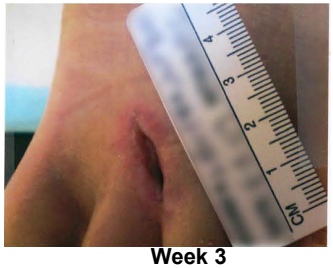
Week 3

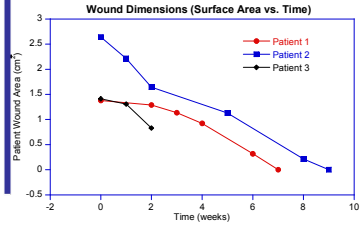

Results:

There were no complications in the combined treatments for the three patients with debrided wounds in this set of cases associated with HBO therapy and the novel powder dressing. The dressing was changed weekly and did not require reapplication between visits. Each wound was resolved to closure.

Conclusions:

It is possible to combine HBO therapy with the application and covering of a debrided wound with a novel powder dressing in the treatment of debrided chronic wounds.

Acknowledgement:

This research was supported by ULURU, Inc.

*Altrazeal Transforming Powder Dressing

2010 SAWC Meeting
Orlando, FL

Kelly A Mauro, PT, CWS
Diabetic Foot Clinic
Comprehensive Diabetes Lower Extremity Amputation Prevention
New Orleans, LA

Development of a Protocol for the Treatment and Resolution of Diabetic Foot Ulcers with Clinical Complications

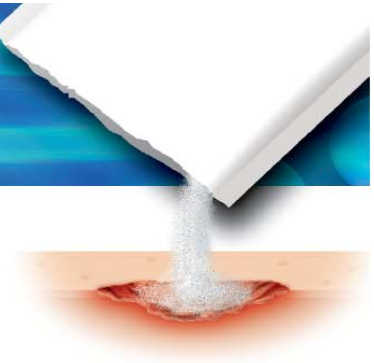

Purpose: The purpose of this evaluation was to test a novel powder wound dressing in the development of a protocol for the treatment of diabetic foot ulcers with mixed concomitant etiologies.
Methods: Wounds with clinical complications including post-op amputation, underlying osteomyelitis, arterial insufficiency and immunosuppression arising from HIV or HCV were studied to determine if a single primary wound dressing can be applied in a protocol that allowed protection of the wound with 7 or 14 day intervals between dressing changes.
The case study presents wounds ranging from 2 years to 4 months in stasis with closure occurring at an interval of 5-10 weeks vs 8-12 weeks in a similar patient population without the application of the primary powder dressing.
The wounds were treated using the novel powder dressing as the primary dressing in contact with the DFU. Th product is applied witha sterile tongue blade. Cadexomer iodine was applied with the powder if the wound had biofilm. The product is used under contact casting with a silicone mesh product used as a secondary dressing between the powder and the cast.
Findings: The case shows shows that the protocol developed with and without offloading allows the application of the powder dressing on the surface of a diabetic foot ulcer. Data is shown for time to healing and photographs of wound progression with dressing changes at 7 or 14 days is shown through healing for all cases.

1. Fitzgerald, R, Bharara, M, Mills, J, Armstrong, DG (2009); " Use of a Nanoflex powder dressing for wound management following debridement for necrotising fasciitis in the diabetic foot" International Wound Journal, 6(2): 133-139.

Patient Post Left Distan Hallux Amputation

Hallux Amputation Closed at 5 Months

5th Metatarsal Ulcer Arose 4 Months Post Hallux Amputation

Hallux Amputation Closed at 5 Months

Clinical Treatment:

59 year old patient treated for two months in HBO wound care department. Patient received s/p left distal hallux amputation one month after treatment for ingrown toenail. The patient was presented to the ER with a wound consisting of 80% devitalized tissue, 20% exposed bone and underlying osteomyelitis. Patient received an arteriogram to assess arterial status due to TBI on LLE 0.35 suggesting severe micro vessel disease and critical limb ischemia. Patient was referred to ortho service for rongeur of exposed proximal phalanx of left hallux and Tenoachilles lengthening to provide gait and pressure relief to enhance healing. Patient's offloading was revised due to the onset of a new ulcer prior to surgery at lateral 5th metatarsal head. Post operatively left hallux wounds measured:(1) 0.3x0.6x0.2 cm (2) 0.5x0.9x0.1cm. The 5th MTH measured:0.8x0.7x0.4 cm probing to tendon. The patient was seen every 7-14 days for selective debridement, application of powder dressing, offloading and self-care, and disease management injury and prevention skills. The hallux post operative wounds closed in three months. At month 6, MTH wound was recultured and were positive. The patient was put on oral antibiotics. Cadexomer iodine gel was added to the powder dressing and a second vascular intervention was performed successfully at month 9. The lateral 5th MTH wound closed at month 10.

2010 APWCA Meeting
Philadelphia, PA

John V. St. John, PhD
ULURU, Inc.

.

Design of Application Protocols for a Transforming Powder Dressing in Common Chronic Wounds

*

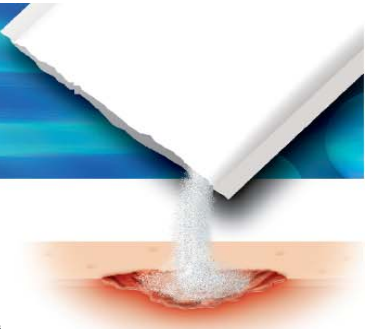

Introduction

Most primary wound dressings have multiple indications for use in chronic wounds. In many cases, clinical data to support healing claims is focused on a narrow type of wound in a specific condition to facilitate scientific endpoints in clinical trial design. The disconnect between clinical data obtained for efficacy and best clinical practice can inhibit basic use and application of products designed to help patients. We present three techniques of clinical application for a novel transforming powder dressing used in the treatment of common chronic wounds.

Methodology

A transforming powder dressing (TPD) was tested in the treatment regimens of three types of chronic wounds:

1) Diabetic foot ulcers combined with total contact cast offloading
2) Venous ulcers with compression dressings
3) Pressure ulcers with depth

In each wound type, an application technique was developed for the specific anatomical location common for the wound. The dressing was evaluated for the capability to remain in place. Secondary dressings and offloading or compression devices were evaluated in conjunction with the TPD to develop simple protocols for applying the products in clinical practice.

Results:

Application protocols have been developed with stepwise instructions for the treatment of three common chronic wound categories using TPD in conjunction with secondary devices such as dressings, total contact casts or compression wraps

DFU with Offloading

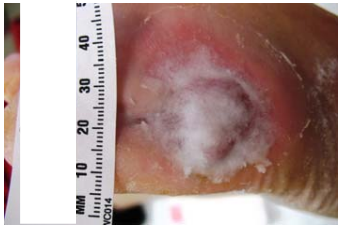

Step 1-Application of TPD over DFU allowing TPD to fully aggregate

Steps 2 and 3-Application of secondary, breathable membrane, and foam over aggregated TPD

Step 4-Immobilization with total contact cast system

Photos Courtesy of Gregory Bohn, MD, FACS

Venous Ulcer

Step 1-Application of TPD over Venous Ulcer and Graft allowing TPD to fully aggregate

Steps 2 and 3-Application of 4-Layer Compression Dressing over aggregated TPD

Step 4-completion of wrapping with 4-layer compression wrap

Photos Courtesy of Kim Eldridge, RN, CNOR, CNFA,, CFCN, WCC

Pressure Ulcer with Depth

Step 1-Transfer of TPD into deep wound using "funnel technique"

Steps 2 and 3-Packing of wound with TPD and repeated applications using funnel and protecting periwound

Step 4-Application of adhesive border dressing with breathable foam pad

Photos Courtesy of Jodie Harper, MD

Techniques

For all wounds shown, proper wound prep including techniques such as debridement, grafting, and treating contamination or infection are essential components of wound management prior to using the transforming powder dressing.

A-DFU with Offloading

1-Plantar surface DFU's requiring offloading can be treated by applying the TPD[1] and allowing the product to fully aggregate forming a complete, intact dressing. This process can take 3-5 minutes after application of the powder.
2-A non-adherent, porous contact layer[2] is applied over the aggregated TPD and fixed in place using tape adhered to the periwound.
3-The wound and foot are wrapped in cotton gauze and foam pads are put into place at the heel and over the offloaded ulcer secured with adhesive tape all supplied with the TCC system[3].
4-The TCC system is applied with the foot held to fix the ulcer in an offloaded position
5-Typical cast and dressing change interval is weekly

B-Venous ulcer with compression

1-Venous ulcers requiring compression can be treated by applying the TPD and allowing the product to fully aggregate forming a complete, intact dressing. This process can take 3-5 minutes after application of the powder.
2-The non-adherent porous membrane material (wound contact layer) supplied with the compression dressing[4] is applied directly to the aggregated powder dressing and held in place without adhesion.
3-The leg is wrapped with the compression dressing, first applying the adsorbent padding layer, then the woven cotton gauze, then the elastic compression dressing and finally the cohesive retaining bandage.
4-Typical compression dressing and TPD change interval is weekly

C-Pressure ulcer with depth

1-Pressure ulcers with depth can be treated by packing the wound with TPD. This is typically accomplished using a modified funnel and packing the TPD with a sterile probe between applications as the powder aggregates.
2-The periwound is cleaned and treated with a protective skin barrier[5].
3-An adhesive border dressing[6] is applied over the wound insuring that the adhesive does not contact the aggregated TPD
4-Typical dressing changes including TPD is weekly

Products

[1]-Altrazeal™ Transforming Powder Dressing-ULURU, Inc.
[2]-Wound Veil-Smith and Nephew, Inc.
[3]-TCC-EZ™-Medefficiency, Inc.
[4]-Profore™ 4-Layer Compression Dressing-Smith and Nephew, Inc.
[5]-Prep Protective Skin Barrier-Coloplast, Inc.
[6]-Mepilex™ Border-Molnlycke Healthcare

Gregory A. Bohn, MD, FACS, Medical Director
Trinity Wound Care and Hyperbaric Medicine
Bettendorf, Iowa

Application of a Novel New Wound Conforming Dressing

Purpose:
The purpose of this presentation is to demonstrate the versatility of a new powder dressing.

Background:
The ideal wound dressing would maintain a moist wound environment, allow gaseous exchange so that oxygen, carbon dioxide and water vapor can pass in and out of the dressing, be thermally insulating, be impermeable to bacteria to protect from contamination, be non-traumatic and not adhere to the wound, be user friendly and easy to apply, remain in place, be cost effective and have minimal need for secondary dressing (2,3,4). Dehydrated particles that contain a methacrylate backbone and a terminal hydroxyl group have been developed such that when placed in a wound and exposed to physiological fluid aggregate into a structural gel that intimately covers the wound (1). Poly-2-hydroxyethylmethacrylate (pHEMA) and Poly-2-hydroxypropylmethacrylate (pHPMA) particles are synthesized as a powder that can be applied into a wound and hydrated with saline by drip method or misting that aggregate into a wound contour conforming dressing (1). When hydrated, this dressing aggregates to a final content of approximately 65% moisture by weight (1). This presentation illustrates uses of this novel new technology with three clinical case studies.

Methods:
A new powder dressing became available. To evaluate this dressing in our clinic, we applied the dressing to a variety of wounds. Applied alone, under compression wraps and under contact casts; this powder dressing was observed for ease of use, staying in place, and for effectiveness in healing wounds by weekly wound measurements (5).

Case 1: A 47 yo Insulin dependent Diabetic white male presented with a neuropathic Wagner Grade 2 ulcer on the lateral aspect of his right foot. He had been treated with an offloading DH Walker and daily dressing with a currently available collagen silver dressing. Wound healing progress had stalled and powder dressing was used under a contact cast to better offload and treat his neuropathic ulcer. A breathable wound veil was placed over the aggregated dressing along with a foam under the cast. The wound healed on a sharp trajectory based on calculated wound volume measurements (Figure 1).

Case 2: A 59 yo white male with chronic venous stasis had been on palliative care with his ulcers for 30 months. He had in the past been treated with bioengineered skin grafts, operative skin grafts, and multiple different wound products. He currently was returning to the clinic for twice weekly Multi-layer compression wrapping. Powder dressing was applied weekly after selective debridement while his compression wraps were changed twice weekly. The powder dressing was applied and covered with veil and absorbent foam under the compression wraps. Patient went on to heal his wounds.

Case 3: A 57 yo white male undergoing active chemotherapy and radiation for intra-cranial metastatic melanoma lost his balance and fell against a steam heat radiator and suffered 3rd degree burn wounds to his right thigh. Concerned that the patient's debility while undergoing active chemotherapy would not support a graft or heal a donor site, dressing therapy was to be used. After debridement of dead eschar, powder dressing was used without a secondary dressing. It stayed in place over the course of the week and reduced the patients pain. His wound healed without grafting.

CASE 1

Diabetic Wagner Grade 2 Neuropathic Ulcer

Application of Powder Dressing

Powder Dressing Covered with Wound Veil

Diabetic Ulcer with Foam Before Contact Cast

Application of Contact Cast

CASE 2

Right Leg Venous Ulcer

Left Leg Venous Ulcer

Powder Application

Powder Dressing Right Leg Venous Ulcer

Powder Dressing Left Leg Venous Ulcer

Compression Wraps Applied After Powder Dressing

CASE 3

3rd Degree Durn Wound to Right Thigh

Application of Powder Dressing

Dressing on Right Leg Burn Wound Aggregating with Saline

Powder Dressing in Place

Third Degree Burn Wound Healed

Powder Dressing and Diabetic Ulcer

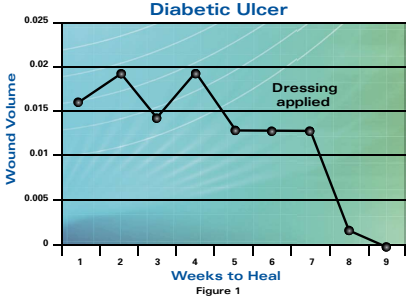

Figure 1

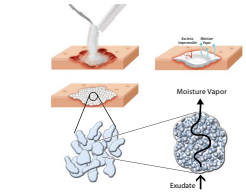

The dressing components consist of polymer particles. The polymer particles are composed of 85% poly-2-hydroxyethylmethacry-late (pHEMA) and 15% poly-2-hydroxypropyl methacrylate (pHPMA). The polymers pHEMA and pHPMA are both non-resorbable, non-degradable, hydrophilic crosslinked polymers that are in the ratio of 85:15 by weight and maintain a fluid content of approximately 68% by weight of the matrix. The powder aggregates (coalesces) immediately and irreversibly from polymer particles into an intact dressing. There is no chemical reaction during dressing formation. The dressing binds together physically and not chemically and remains bound together with the wound exudate through hydrophilic/hydrophobic interactions, hydrogen bonding and VanDerWaal forces. An illustration of the dressing displaying the mechanism of action is shown.

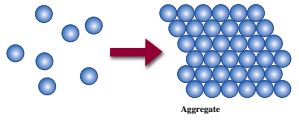

Aggregate

Conclusions:
Powder dressing is a versatile new wound dressing material that can be applied in a variety of wound conditions. The ability to leave the dressing in place for up to 30 days is a characteristic that is desirable in applications where dressings aren't typically changed daily. Treating wounds under contact casting is one such application. Dressing worked well under contact casting in the treatment of diabetic neuropathic ulcers. A similar observation was made in use in conjunction with compression wrapping of venous stasis wounds. Although the compression wraps were changed twice weekly according to our protocol, the dressing was left in place for the week and changed at the patients weekly physician visit after debridement. In treatment of burn wounds, this dressing reduces pain and does not require frequent changes which also reduces painful dressing change episodes. It stays in place and does not require a secondary dressing. This treatment brought about healing of a third degree burn wound in a difficult patient who was undergoing active chemotherapy. Dressing worked well in these 3 applications and all three wounds healed.

References:
1.) St. John J V, Brown S A.,Hatef DA, Unzeitig A W, Noble D, Waller L K, and Ponder B C. Formulation development and in vivo testing of a novel powder wound dressing. The University of Texas Southwestern Medical Center at Dallas, Department of Plastic Surgery, 1801 Inwood Rd., Dallas, TX 75390
2.) Turner TD. Products and their development in wound management. Plast Surg Dermatol Aspects. 1979; 75-84
3.) Thomas S, Loveless P. A comparative study of the properties of six hydrocolloid dressings. Pharm J 1991; 247:672-675.
4.) Sharman D, Moist wound healing: a review of evidence, application and outcome – Review. Diabetic Foot, The Autumn 2003.
5.) Kantor J, Margolis DJ. Efficacy and Prognostic Value of Simple wound Measurements. Arch Dermatology. 1998; 134: 1571-1574.

TRINITY IOWA HEALTH SYSTEM
A better experience.
Diversified Clinical Services
Healing Wounds. Changing Lives.
ULURU, Inc.