

Treatment of Hardware Infection after Osteosynthesis of Lower Leg using Negative Pressure Wound Therapy and Transforming Powder Dressing

Marin Marinović¹, Aldo Ivančić¹, Josip Španjol², Maja Pin³, Bore Bakota⁴, Ante Bandalović⁵ and Fabijan Čukelj⁵

¹ Department of Surgery, University Hospital of Rijeka, Rijeka, Croatia

² Department of Urology, University Hospital of Rijeka, Rijeka, Croatia

³ Faculty of Medicine, University of Rijeka, Rijeka, Croatia

⁴ Department of Traumatology, General Hospital of Karlovac, Karlovac, Croatia

⁵ Department of Surgery, University Hospital of Split, Split, Croatia

ABSTRACT

Fractures of the distal part of the lower leg are more common in everyday practice and traumatology. In young and active patients these injuries are mainly caused by high energy trauma. They are treated with external fixator in first step, and in second step, after sanation of the soft tissue, with open reduction and internal fixation (ORIF). It is very safe and effective method of treatment. Treatment of the infections that occur in the early postoperative period after open reduction and internal fixation represents a great problem and challenge for surgeons. It is widely accepted that the presence of deep infection can't be cured in the presence of hardware. However, removal of hardware in the presence of unhealed fractures significantly complicates sanation of infection and fracture itself. We have decided to present a 35-years-old patient with a hardware infection with present chronic wound with hardware exposed eight months after the first operation and six months after second operation. The wound measured one centimeter in diameter with cell detritus and bad granulations tissue inside the wound. Hardware was exposed in the depth of the wound. The secretion was minimal. Negative Pressure Wound Therapy (NPWT) was applied after debridement and lavage performed in ambulatory conditions. The starting therapy was continuously -125 mm Hg of vacuum. After five days of NPWT the defect was partially filled with granulation tissue. For another five days we continue with NPWT with the same values of -125 mm Hg pressure but in the intermittent mode. After that period we used transforming powder dressing for covering and protection of the wound with was filled with granulation tissue. Five days later, wound was completely healed with epithelisation. After four months of patient follow-up, we found the wound is completely repaired. The patient denies pain and has continued orderly flow of fracture healing, with no signs of infection.

Key words: hardware infection, NPWT, transforming powder dressing, lower leg fracture

Introduction

Treatment of infection that occurs in early postoperative period after the open reduction and internal fixation (ORIF) treatment of fractures is still a dilemma in surgical circles. There is a broadly accepted opinion that the occurrence of deep infection can not be cured in the presence of osteosynthetic material^{1,2}. However, removal of hardware in the presence of non-union fracture significantly complicates sanation of infection and fracture healing. Standard orthopedic dogmas suggests that fractures can be treated in presence of infection as long as the osteosynthetic mate-

rial remains stable³⁻⁶. Standard treatment of deep acute infection after ORIF is lowering of bacterial load with irrigation and debridement as well as treatment of the infection in the area of the bone healing⁷. Negative Pressure Wound Therapy (NPWT) has an important role in treatment of traumatic wounds since the 1990s. There is even a greater role in treatment of postoperative care that includes stabilization of the wound environment, reduction of oedema, improving the tissue perfusion, as well as a cell stimulation in the wound surface⁸. Negative Pressure

Wound Therapy stimulates growth of granulation tissue, angiogenesis and contributes to primary wound closure. As well, it decreases the need for the free tissue transfer for the wound closing. Mentioned therapy has an influence in decreasing the number of bacteria in the wound as well as the reduction of the amount of harmful products in the wound (endo- and egzotoxins, cytokines and matrix metalloproteinases)⁹. The use of NPWT in this case is indicated for the purpose of early wound closing. The most important effect is stimulation of granulation synthesis above the braditrophic tissue even over the osteosynthetic material, which is the fastest among the all wound dressing techniques. There are cases that describe that in smaller defects granulations can fill the whole defect so it is possible the skin graft placement without the need for the flap reconstruction^{10–12}. Transforming powder (ALTRAZEAL[®], Uluru Inc., Addison, TX, USA) is flexible methacrylate dressing. It consisted of microscopic particles of poly-2-hydroxyethyl-/poly-2-hydroxypropyl (pHEMA/pHPMA) – methacrylate backbone and terminal hydroxyl group with minimal size of 60–65 µm. That is a sterile powder that fills and seals the wound like a three-dimensional dressing. The powder particles aggregate irreversibly after the contact with the wound exudate and synthesize moist, flexible cover that makes ideal environment for wound healing. The cover enables optimal oxygen and water steam transpiration in the wound, impermeability for microorganisms, tensile strength and flexibility. Results of Forstner and authors indicate that this flexible methacrylate dressing also can be loaded with various antiseptics serving as drug delivery system¹³.

Case report

Thirty-five year old patient has been admitted in the trauma outpatient clinic. Eight months before coming to the department he was participating in a traffic accident as a motorcycle driver. He suffered from a simple spiral fracture of the diaphysis of the right tibia (AO 42-A1). He has been surgically treated in another institution and intramedullary osteosynthesis with expert tibial nail was done. After two months of the operation, a reoperation was done. The broken nail was removed and open reduction and internal fixation with the locking compression plate (LCP) was performed. Since then, in pretibial area a skin defect in radius of approximately one centimeter persists. The patient was treated in the outpatient clinic with different kind of dressings with antibiotic support on the basis of susceptibility testing. The last result of microbiological analysis was positive to *Staphylococcus* spp. (coagulase negative). The antibiotic Azithromycin (*Sumamed[®]*) in appropriate dose was prescribed by the family practice doctor. The blood samples result at the time of admission were: C-reactive protein 9.8 mg/dL, white blood count 11.2×10^9 , erythrocyte sedimentation rate (ESR) of 25 mm/h. Patient was subfebrile 37.3 °C. The defect was persisted with uneven, violaceous edges with minimal secretion. In the bottom of the defect osteosynthetic material was visible. Patient quotes tactile pain immediate near

the defect. Allergies as well as other comorbidities have been declined.

Before the application of NPWT we conducted debridement by which we removed the cell detritus and hypotrophic granulations. The result of that procedure was satisfying capilar bleeding from the edges of the wound. In the bottom of the wound osteosynthetic material was exposed. Profuse lavage was conducted with the saline solution (Figure 1). Negative pressure dressing set was applied. Because of the small radius of the defect, firstly the NPWT set foil was applied of the wound area in the radius of approximately five centimeter. Wound print was cut off and poliurethan (PU) foam, that was volume adequate, was applied. Bigger radius foam was applied afterwards with the »sandwich« technique and associated suction pad. Initial negative pressure therapy was –125 millimeter of mercury in continuous mode. Five days after we changed the negative pressure dressing set (Figure 2). Wound defect was partially filled with healthy well vascularized granulations that completely covered the osteosynthetic material in the bottom of the wound. The therapy was continued with the same values of –125 mm Hg pressure but in the intermittent mode. After five days, healthy well vascularized tissue filled the whole defect. We stopped with the negative pressure therapy. A control swab was conducted for the microbiological analysis. We continued the treatment with the transforming powder. We applied the powder evenly as a 3 mm thick layer and with the help of the saline solution we transformed it in the gelatinous state. Five days later we changed the transforming powder dressing (Figures 3 and 4). Defect epithelized completely. The surrounding skin was orderly colorized and eutermic, without any signs of hyperemia or infection (Figure 5).

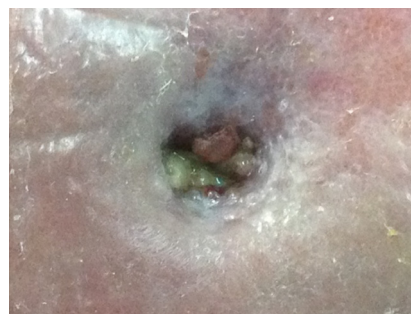

Fig. 1. Initial wound presentation.

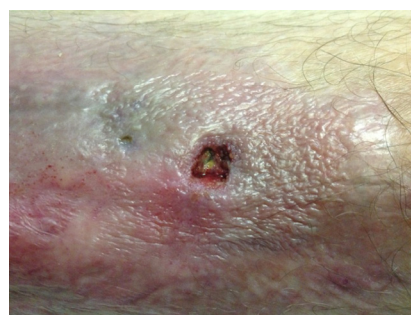

Fig. 2. Wound after five days of using NPWT.

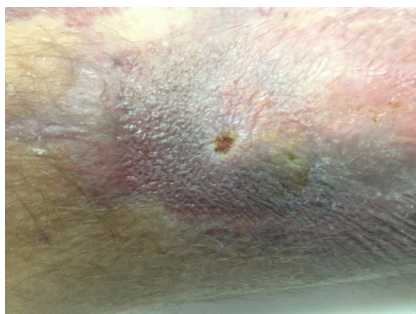

Fig. 3. Wound after ten days of using NPWT.

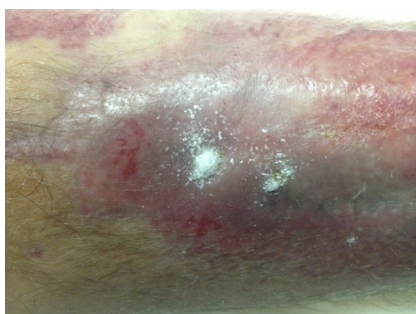

Fig. 4. Using of Altrazeal®.

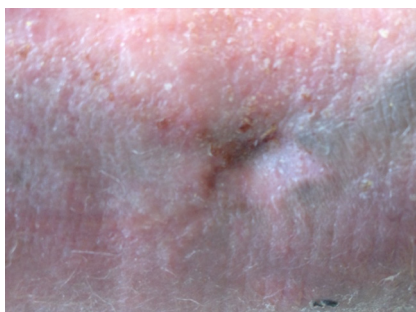


Fig. 5. Wound epithelization.

The control laboratory results were within the reference range. The patient negated pain, itching or any other unpleasant sensations. On the control examination after four months, local soft tissue status was satisfactory. Area of previous defect was slightly colorized comparing to the surrounding skin, but without any local inflammation signs. Radiological evaluation showed a good bone healing process, with the good calus and without any signs of the bone inflammation. The patient negates pain or any other unpleasant sensations. He conducted the rehabilitation activities without any problems, adjusted to the process of the bone reparation.

Discussion

Fractures of the distal third of the leg are more and more common in everyday traumatology practice. They are mostly caused by low energy trauma in elderly people, while in the younger and active patients it is mostly caused

by high energy trauma¹⁴. This kind of trauma is treated mostly surgically by open reduction and internal fixation, which are a safe and efficient ways of treating low energy fractures^{15–17}. In high energy fractures placement of external fixation in the first period is recommended due to soft tissue damage control. After the soft tissue damage sanitation, definitive fixation is recommended¹⁸. There is a risk of possible complications of exposure and infection in the presence of the osteosynthetic material, especially after the high energy trauma. This can lead not only to the healing delay and deep infection, but also to algodystrophy, delay of the fracture healing, joint stiffness and poor functional result. This condition indicates the removal of the material and delayed reconstruction of the soft tissue. Guidelines for the procedure are removal of the osteosynthetic material, debridement, irrigation and antibiotic therapy. In order to prevent the destabilization of the fracture, due to the removal of the osteosynthetic material, the placement of the external fixation is indicated. However, immediate soft tissue reconstruction is still possible in selected patients, without moving the hardware¹⁹. Covering of this type of defects with the exposed hardware and transplantation of partial skin thickness graft can result in poor functional result, so it is not a recommended solution in most of the cases. That is a challenge for the operator because of the thick skin layer above the bone and fragile tangle of blood vessels so the soft tissue reconstruction should be done as soon as possible^{20,21}.

Appearance of the Negative Pressure Wound Therapy since twenty years ago has significantly contributed and improved the treatment of all kinds of traumatic wounds, and is lately more used in postoperative wounds with traumatic etiology with secondary healing and with the presence of osteosynthetic material in the body. All of that results in great number of saved extremities that would otherwise be amputated²². However, surgical exploration and the debridement of the wound with necrectomy stay the first and most important treatment of mentioned injuries. Removal of all necrotic tissue and avital bones in the wound give a good base for granulation tissue proliferation and a start of a healing process as well as prevent the further infection progress²³. Local application of NPWT speeds up and amplifies healing mechanisms, even in the injuries with compromised microcirculation primarily contaminated wounds and haematoma²⁴. With the use of the Negative Pressure Wound Therapy open wound converts in controlled and temporarily closed wound so the favourable local conditions are reached in the presence of the healthy granulation tissue. With this kind of satisfactorily local status, surgical techniques can be used to close the wound defect. If the defect is smaller like in the case of shown patient, it is not necessary to implement reconstruction with the local or distant lobe, but should assure adequate conditions so the defect can be epithelized. In the case of our patient, we assured this conditions with the use of transforming powder dressing (ALTRAZEAL®). After the short contact with the exudate from the wound, particles of the transforming powder particles aggregated irreversibly and synthesize moist, flexible cover that makes ideal environment for wound healing. The cover en-

ables optimal oxygen and water steam transpiration in the wound, impermeability for microorganisms, tensile strength and flexibility. These conditions enabled unobstructed epithelisation and closing of the wound, minimizing the possibility of reinfection.

Conclusion

The use of Negative Pressure Wound Therapy in patient with postoperative wound and the presence of hardware is shown like a justified therapeutic choice. Local

conditions have been made for the synthesis of »good« vascularized granulation tissue that filled the wound defect and covered osteosynthetic material. The use of transformation powder assured better conditions for the process of wound epithelization and definite closure of the defect. This case could be a guideline in processed surgical postoperative treatment and shows that the extraction of osteosynthetic material does not have to be the first choice in infection treatment. Combination of quality surgical wound treatment and the use of new techniques and methods can result positively like in this case.

REFERENCES

1. DELLAMONICA P, ETESE-CARSENTI H, BERNARD E, MONDAIN V, DURANT J, ARGENSON C, J Antimicrob Chemother, 26 (1990) 199. — 2. PELHAM FR, KUBIAK EN, SATHAPPAN SS, DI CESARE PE, J Wound Care, 15 (2006) 111. — 3. COURT-BROWN CM, KEATING JF, MCQUEEN MM, J Bone Joint Surg Br, 74 (1992) 770. — 4. HOFMANN GO, BAR T, BUHREN V, Chirurg, 68 (1997) 1175. — 5. WORLOCK P, SLACK R, HARVEY L, MAWHINNEY R, Injury, 25 (1994) 31. — 6. WORLOCK P, SLACK R, HARVEY L, MAWHINNEY R, Br J Exp Pathol, 69 (1988) 235. — 7. MADER JT, CRIPPS MW, CALHOUN JH, Clin Orthop Relat Res, 360 (1999) 14. — 8. STREUBEL PN, STINNER DJ, OBREMSKEY WT, J Am Acad Surg, 20 (2012) 564. — 9. HULJEV D, NOVINŠČAK T, GVERIĆ T, Acta Med Croatica, 65 (2011) 81. — 10. DE FRANZO AJ, ARGENTA LC, MARKS MW, MOLNAR JA, DAVID LR, WEBB LX, WARD WG, TEASDALL RG, Plast Reconstr Surg, 108 (2001) 1184. — 11. MULLNER T, MRKONJIC L, KWASNY O, VECSEI V, Br J Plasr Surg, 50 (1997) 194. — 12. PELHAM FR, KUBIAK EN, SATHAPPAN SS, DI CESARE PE, J Wound Care, 15 (2006) 111. — 13. FORSTNER C, LEITGEB J, SCHUSTER R, DOSCH V, KRAMER A,

CUTTING KF, LEAPER DJ, ASSADIAN O, J Mol Sci, 14 (2013) 10582. — 14. CALORI GM, TAGLIABUE L, MAZZA E, DE BELLIS U, PIERANNUNZII L, MARELLI BM, COLOMBO M, ALBISETTI W, Injury, 41 (2000) 1183. — 15. AYENI JP, Injury, 19 (1988) 109. — 16. BRENNAN MJ, Instr Course Lect, 39 (1990) 167. — 17. TEENY SM, WISS DA, Clin Orthop Relat Res, 292 (1993) 108. — 18. PUGH KJ, WOLINSKY PR, MCANDREW MP, JOHNSON KD, J Trauma, 47 (1999) 937. — 19. VIOLA A, PRADKA SP, BAUMEISTER SP, WANG D, MOYER KE, ZURA RD, OLSON SA, ZENN MR, LEVIN SL, ERDMANN D, Plast Reconstr Surg, 123 (2009) 1256. — 20. VAIENTI L, DIMATTEO A, GAZZOLA R, PIERANNUNZII L, PALITTA G, ANDREA M, Journal of Orthopaedic Surgery and Research, 7 (2012) 30. — 21. NIEMINEN H, KUOKKANEN H, TUKIAINEN E, ASKO-SELJAVAARA S, J Trauma, 38 (1995) 660. — 22. CLEMENTS JR, MIERISCH C, BRAVO CJ, J Foot Ankle Surg, 51 (2012) 118. — 23. GEISSLER W, TEASEDALL R, TOMASIN J, HUGHES J, J Ortop Trauma, 4 (1990) 39. — 24. BAKOTA B, KOPLJAR M, JURJEVIC Z, STARESINIC M, CVJETKO I, DOBRIC I, DE FAOITE D, Coll Antrop, 36 (2012) 1419.

M. Marinović

Department of Surgery, University Hospital of Rijeka, Tome Strižića 3, 51 000 Rijeka, Croatia
e-mail: marin.marinovic12@gmail.com

LIJEČENJE INFEKCIJE NAKON OSTEOSINTEZE POTKOLJENICE POMOĆU NEGATIVNOG TLAKA I PREVOJA TRANSFORMIRAJUĆIM PRAHOM

SAŽETAK

Lomovi distalnog dijela potkoljenice su česti u svakodnevnoj praksi i traumatologiji. U mladih i aktivnih pacijenata ove ozljede uglavnom su uzrokovane traumom visoke energije. Te ozljede se liječe postavljanjem vanjskog fiksatora u prvoj fazi liječenja, a u drugoj fazi, nakon sanacije mekog tkiva, otvorenom repozicijom i unutarnjom fiksacijom (ORIF). To je vrlo siguran i učinkovit način liječenja. Liječenje infekcija koje se javljaju u ranom poslijeoperacijskom periodu nakon otvorene repozicije i unutarnje fiksacije je veliki problem i izazov za kirurga. Opće prihvaćen je stav da se duboka infekcija ne može izliječiti u prisutnosti osteosintetskog materijala u rani. Međutim, uklanjanje osteosintetskog materijala u situaciji nezaraslog prijeloma značajno komplicira sanaciju infekcije i liječenje samog prijeloma. Odlučili smo prezentirati 35-godišnjeg pacijenta s infekcijom i kroničnom ranom uz prisustvo osteosintetskog materijala u rani. Rana je mjerila jedan centimetar u promjeru sa staničnim detritusom i lošim granulacijskim tkivom unutar rane. Osteosintetski materijal je bio izložen u dubini. Terapiju negativnim tlakom (TNT) smo primijenili nakon debridmana i ispiranja u ambulantnim uvjetima. Početna terapija je bila kontinuirana u vrijednosti od –125 mm Hg vakuuma. Nakon pet dana primjene TNT defekt rane je djelomično bio ispunjen granulacijskim tkivom. Nakon pet dana primjene, nastavili smo s TNT s istim vrijednostima od –125 mm Hg, ali u intermitentnom modusu. Nakon deset dana uporabe TNT, koristili smo transformirajući puder u prahu za pokrivanje i zaštitu rane u procesu epitelizacije. Nakon pet dana, rana je u potpunosti epitelizirala. Nakon četiri mjeseca na kontrolnom pregledu vidjeli smo da je rana u potpunosti sanirana. Pacijent nije navodio boli, a proces zacijeljivanja prijeloma nastavio se očekivanim tijekom.